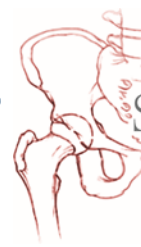

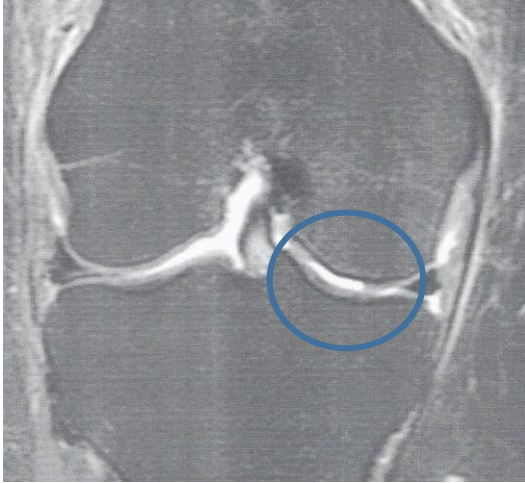Fallbeispiel CaReS-1S

MRT – Verlauf Patientin 53 J.

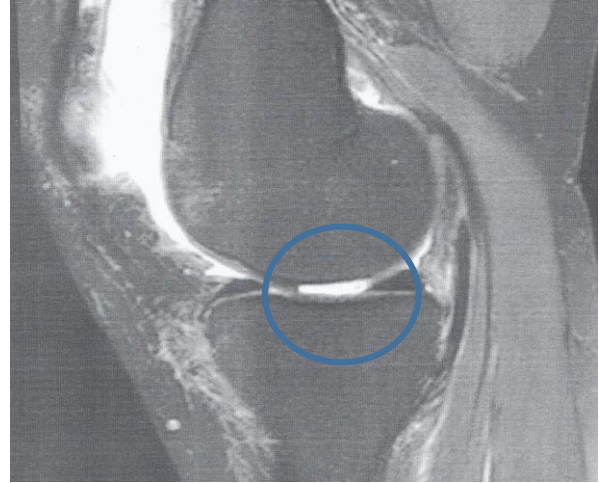
OP – Datum 27.09.2019



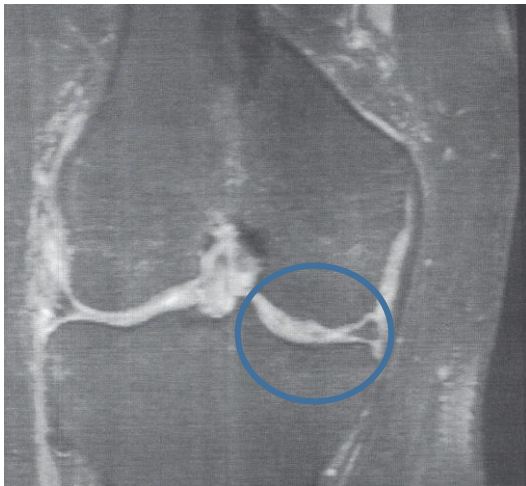
SPONGIO TECH



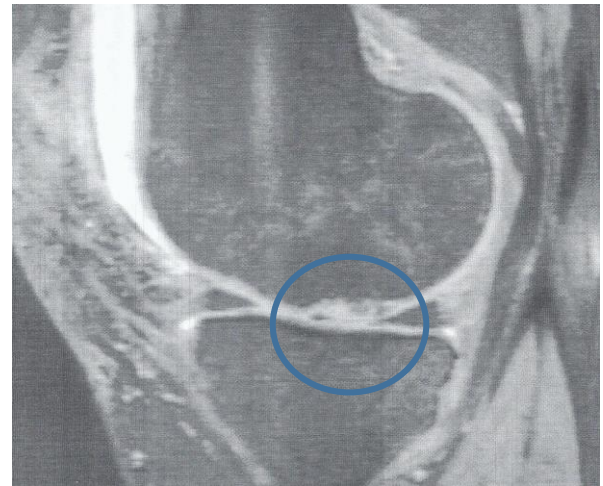
pre – OP 12.09.2019



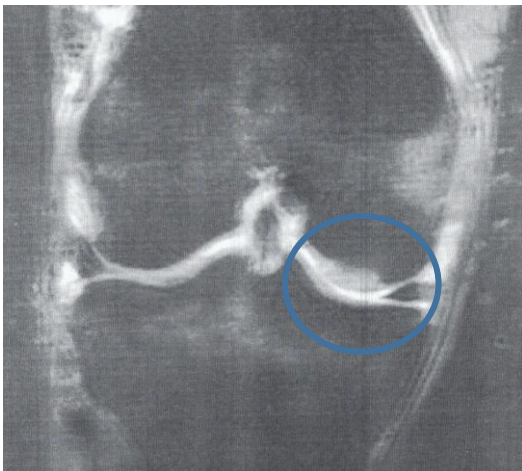
Knorpeldefekt Femurkondyle
Implantation CaReS-1S 22x4 mm



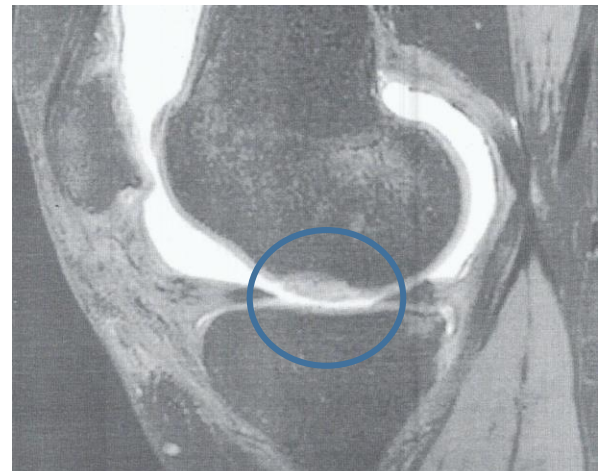
Verlauf 12.02.2020



Umbau des Implantates in
hyalinartigen Knorpel



Verlauf 29.04.2020



Vollständige Defektauffüllung